CURRENT THERAPEUTIC RESEARCH

VOLUME 69, NUMBER 6, DECEMBER 2008

Effects of Silymarin and Pentoxifylline on Matrix Metalloproteinase-1 and -2 Expression and Apoptosis in Experimental Hepatic Fibrosis

Eray Kara, MD; Teoman Coşkun, MD; Yavuz Kaya, MD; Okan Yumuş, MD; Seda Vatansever, MD; and Ahmet Var, MD

Medical School, Celal Bayar University, Manisa, Turkey

ABSTRACT

BACKGROUND: Many therapeutic strategies have been proposed to treat liver fibrosis, but no drugs have been proved effective. Matrix metalloproteinases (MMPs) have been reported to play a role in some cellular cascades of hepatic inflammation and fibrosis.

OBJECTIVE: The purpose of this study was to investigate whether silymarin and pentoxifylline (PTX) have hepatoprotective and antifibrotic effects in experimental hepatic fibrosis.

METHODS: Sprague-Dawley rats were divided into 4 groups: silymarin group (silymarin 4 mg/kg · d^{-1} orally, common bile duct ligation [CBDL]); PTX group (PTX 2 mg/kg · d^{-1} intraperitoneally, CBDL); sham group (common bile duct [CBD] exploration only); and control group (saline 1 mL/d orally, CBDL). The CBD was explored and dissected sufficiently to allow passage of a 3/0 silk suture via midline laparotomy. On day 10, all animals were euthanized via cervical dislocation. Then, 5-cm^3 liver samples from the right lobe were removed for histomorphologic evaluation and 3-mL blood samples were taken via cardiac puncture for biochemical analyses. Apoptosis was determined using the terminal deoxynucleotidyltransferase-biotin nick end-label (TUNEL) staining method. Plasma levels of aspartate aminotransferase (AST), alanine aminotransferase (ALT), and γ-glutamyltransferase; total and indirect bilirubin concentration; hepatic MMP-1 and -2 and tissue inhibitor of MMP (TIMP)-1 and -2 activity; and transforming-growth factor (TGF)-β_1 concentration were measured. Collagen content was determined by measuring hydroxyproline in liver samples. Malondialdehyde (MDA) was used to estimate lipid peroxidation.

RESULTS: Thirty-two adult male Sprague-Dawley rats were divided into 4 groups: silymarin group (n = 7), PTX group (n = 7), sham group (n = 9), and control group (n = 9). Compared with the control group (14.6 [2.44]), mean (SD) hepatocyte apoptosis (as measured by the ratio of TUNEL-positive cells) was significantly suppressed in the silymarin group (1.2 [0.13]; $P = 0.001$) and the PTX group (3.8 [0.34]; $P = 0.001$). Mean (SD) MMP-2 activity in the silymarin group (57.35 [9.89] μg/mL; $P = 0.04$) and the PTX group (46.88 [9.56] μg/mL; $P = 0.04$) was significantly lower than that observed in the control group (232.32 [79.76] μg/mL). Compared with the con-

Accepted for publication September 29, 2008.
© 2008 Excerpta Medica Inc. All rights reserved.
doi:10.1016/j.curtheres.2008.12.003
0011-393X/$32.00

trol group (1.37 [0.38] μg/mL), TIMP-2 activity was significantly lower in the silymarin group (0.55 [0.13] μg/mL; $P = 0.04$) and the PTX group (0.42 [0.09] μg/mL; $P = 0.01$). Compared with the control group (909.17 [117.35] μg/mL), TGF-β_1 was significantly lower in the silymarin group (518.24 [30.34] μg/mL; $P = 0.01$) and the PTX group (519.57 [47.27] μg/mL; $P = 0.01$). Histomorphologic changes were significantly greater in the sham group than in the silymarin and PTX groups: hemorrhage (2.44 [0.29] vs 1.29 [0.18] and 1.57 [0.20], respectively; both, $P = 0.04$); sinusoidal dilatation (2.22 [0.22] vs 1.57 [0.20] and 1.71 [0.18]; both, $P = 0.04$); presinusoidal polymorphonuclear cell infiltration (3.44 [0.24] vs 2.57 [0.20] and 2.14 [0.26]; $P = 0.03$ and $P = 0.008$, respectively); and inflammation (3.44 [0.24] vs 2.57 [0.20] and 2.14 [0.26]; $P = 0.03$ and $P = 0.008$, respectively). In the control group, all biochemical markers were elevated, supporting the presence of liver injury. Compared with the control group (630.00 [46.80] U/L), plasma AST activity was significantly lower in the silymarin group (443.11 [78.73]; $P = 0.04$) and the PTX group (349.42 [34.00]; $P = 0.03$). Compared with the control group (191.12 [32.93] U/L), plasma ALT activity was significantly lower in the silymarin group (86.14 [4.97]; $P = 0.04$) and the PTX group (84.14 [11.21]; $P = 0.04$). MDA concentration was significantly lower in the silymarin group compared with the control group (0.08 [0.01] vs 0.22 [0.03] nmol/mL; $P = 0.004$); MDA was also significantly lower in the silymarin group than in the PTX group (0.11 [0.02]; $P = 0.03$).

CONCLUSIONS: Silymarin and PTX were associated with lower histopathologic liver damage, hepatocyte apoptosis, and regulation of extracellular matrix proteins. Lipid peroxidation in hepatocytes was significantly lower in the silymarin group compared with the PTX group. Silymarin and PTX appeared to have hepatoprotective effects in this experimental liver fibrosis model, but further clinical and experimental studies are needed. (*Curr Ther Res Clin Exp.* 2008;69:488–502) © 2008 Excerpta Medica Inc.

KEY WORDS: matrix metalloproteinases, MMP-1, MMP-2, tissue inhibitor of matrix metalloproteinases, TIMP-1, TIMP-2, experimental liver fibrosis, apoptosis.

INTRODUCTION

Liver cirrhosis is the terminal stage of a variety of chronic active liver diseases with different etiologies, among which nutritive-toxic, alcohol, viral, immunologic, and parasitic injuries prevail.[1] Liver injury is associated with the activation of hepatic stellate cells (HSCs). The resulting secretion of matrix by activated HSCs results in liver fibrosis and ultimately in cirrhosis.

Cirrhosis and fibrosis are both irreversible and may progress.[2] Hepatic fibrogenesis is a dynamic unity of liver cells and extracellular matrix (ECM) proteins. Major changes in the quality and the amount of hepatic ECM with hepatocellular cells, HSCs, and depot cells, and activation of lipocytes play a major role in regeneration of ECM.[2]

Studies have reported that the excessive accumulation of ECM in liver is a dynamic and bidirectional process that is mainly regulated by HSCs that become activated and develop a myofibroblast-like phenotype that is associated with increased proliferation

and collagen synthesis.[2,3] Several in vitro studies found that HSC activation results from the complex interplay of different variables, such as cytokines, growth factors, oxidative stress, and modification of sodium/hydrogen ion-exchange activity.[4,5] Although traditionally viewed as irreversible, reversibility of liver fibrosis has been described.[3] Targeting antifibrotic drugs to HSCs is currently a promising strategy for blocking fibrotic processes leading to liver cirrhosis. Therefore, finding a proper pharmacotherapeutic treatment for liver fibrosis is considered a priority.[6]

Matrix metalloproteinases (MMPs) released from hepatocytes and Kupffer cells can degrade multiple ECM components.[5–7] Interstitial collagenase MMP-1 is released from the liver. MMP-2 and MMP-14 have interstitial collagenic activity that decreases in chronic liver disease, resulting in collagen accumulation.[6–8] Tissue inhibitor of MMP (TIMP)-1 and TIMP-2 activity increase in association with hepatic fibrosis.[5–9] Increasing the TIMP/MMP ratio induces hepatic fibrosis through MMP inhibition of the degradation of ECM in liver. As a result, overexpression of ECM by activated liver cells, reduction of MMP activation, and inhibition of active MMPs by TIMPs induces fibrogenesis. Therefore, removing activated liver cells by apoptosis may have a therapeutic effect, stopping or even reversing the fibrogenic process in liver.[7–9] However, a study in patients with chronic hepatitis due to hepatitis C virus infection found that hepatic MMP-2 and MMP-9 activity in leukocytes increased, whereas TIMP-2 activity in mononuclear leukocytes decreased.[10] The degree of inflammation and fibrosis did not correlate with either MMP-9 or TIMP mRNA production.

Hepatic scarring is the result of a dynamic process that balances fibrogenesis and fibrolysis.[11] Fibrogenesis is a result of excess synthesis and deposition of ECM. The early phase of fibrogenesis occurs in the subendothelial space of Disse. The cells in this region include endothelial cells, hepatocytes, Kupffer cells, and HSCs. HSCs are the main source of extracellular matrix.[11] Quiescent HSCs transform into myofibroblast-like cells and proliferate.[11,12] Several cytokines are thought to be involved in the signaling of this process: fibroblast growth factor, transforming growth factor (TGF)-β_1, interleukin-1 and -2, tumor necrosis factor (TNF), monocyte chemoattractant protein, platelet-derived growth factor (PDGF), and endothelin-1.[12] Fibrolysis relies on collagenases, such as metalloproteinases. TIMPs are found in pathologic conditions, such as cirrhosis.[11–13]

There are 2 types of liver fibrosis: portal/septal fibrosis and perisinusoidal fibrosis.[11] Portal fibrosis, the most prominent morphologic feature in cirrhosis, represents a major architectural disturbance. Although perisinusoidal fibrosis is observed in cirrhosis, it can be the unique cause of portal hypertension (ie, vitamin A intoxication).[11] Perisinusoidal fibrosis involves overproduction of ECM components, which leads to the capillarization of sinusoids. Hepatic ECM was originally considered a metabolically inert material that serves as a framework for the functionally important parenchyma.[11–13] To the contrary, ECM of liver and of other epithelial-mesenchymal organs is a complex assembly of macromolecules that rapidly undergoes remodeling after injury. The molecules of hepatic ECM have been subdivided into collagens, noncollagenous glycoproteins, glycosaminoglycans, proteoglycans, and elastin.[13]

Silymarin is a standardized extract of the milk thistle (*Silybum marianum*) whose main active compounds are the flavonoids silybin, silychristine, and silydianin, with silybin accounting for ~60% of the composition.[14] Silymarin has been reported to possess hepatoprotective properties in both in vitro and in vivo studies.[15–17] In liver fibrosis, silybin was found to reduce activation and proliferation of isolated and cultured HSCs and to reduce collagen accumulation in experimental liver fibrosis in rats.[18–20] Silymarin is a potent antioxidant that inhibits lipid peroxidation in hepatocytes.[20–22] It has also been reported to have anti-inflammatory activities mediated by alteration of hepatic Kupffer cell function.[23]

Pentoxifylline (PTX) may target fibrotic liver.[5,6,14–16] Its antifibrogenic and anti-inflammatory effects on activated HSCs have been reported.[24–27] PTX reduces the transdifferentiation of HSCs to myofibroblasts and inhibits HSC proliferation.[24,25] PTX has also been reported to reduce the fibrogenic effect of TGF-β on HSCs by interfering with p38 mitogen-activated protein kinase and extracellular signal-regulated protein kinase 1/2 pathways, thereby decreasing hepatic procollagen type 1 mRNA expression. However, profibrotic effects of PTX on Kupffer cells have been reported.[26,27] The objective of this study was to investigate the hepatoprotective and antifibrotic effects of silymarin and PTX in a rat model of liver fibrosis.

MATERIALS AND METHODS

ANIMALS

Adult male Sprague-Dawley rats (weight, 180–200 g) were kept on an artificial 12-hour light-dark cycle and given access to standard rat chow and water ad libitum, according to the National Institutes of Health publication *Guide for the Care and Use of Laboratory Animals*.[5,7,16] Experiments were carried out in compliance with guidelines prescribed by the Institutional Animal Care and Use Committee of Ege University School of Medicine (Ege, Turkey). The Research Ethics Committee of the School of Medicine of Ege University approved the study protocol.

EXPERIMENTAL DESIGN AND SURGICAL PROCEDURE

The animals were allocated, using a randomization table, into 4 groups: PTX group (PTX 2 mg/kg · d^{-1} intraperitoneally, common bile duct ligation [CBDL]); silymarin group (silymarin 4 mg/kg · d^{-1} orally, CBDL); sham group (common bile duct [CBD] exploration only); and control group (saline 1 mL/d orally, CBDL). All animals were anesthetized using vaporized isoflurane (Abbott Laboratories, North Chicago, Illinois). CBDL was used to create extrahepatic obstruction that would cause cholestasis, liver damage, and fibrosis, as previously described in the literature.[28] We preferred the CBDL method, as it is now being used for experimental liver fibrosis models and is easy to perform, especially in rats. A midline laparotomy was performed and the CBD was dissected sufficiently to allow passage of a 3/0 silk suture. Sham-operated animals underwent an identical laparotomy, except that CBD was merely identified without ligation. On day 10, all animals were sacrificed via cervical dislocation. The liver and CBD were exposed through a midline incision. Tissue samples (5 cm^3) from the right lobe were removed for histomorphologic evaluation and blood

samples (3 mL) were taken via cardiac puncture for biochemical analyses. Plasma levels of aspartate aminotransferase (AST), alanine aminotransferase (ALT), and γ-glutamyltransferase (GGT); serum concentrations of total and indirect bilirubin; tissue activity of MMP-1 and -2 and TIMP-1 and -2; and TGF-β_1 and hepatic hydroxyproline concentrations were measured. Malondialdehyde (MDA) concentration was used to estimate lipid peroxidation. A technician who was blinded to treatment group analyzed the liver and blood samples.

Tissue Collection and Fixation

All samples were fixed in a 10% formalin solution. Samples were then washed with tap water and soaked in a series of 50%, 60%, 70%, 80%, and 90% ethanol for 30 minutes and then in 95% and 100% ethanol for 1 hour. They were then held in a solution of 100% ethanol and xylene (1:1 ratio) for 30 minutes, embedded in paraffin, and held at 60°C for 1 hour to create paraffin blocks.

Hydroxyproline Concentration and Collagen Content

Tissue hydroxyproline concentration was determined using a modification of the method described by Chiariello et al.[29] Tissue samples were dried to a constant weight at 60°C and acid-hydrolyzed in sealed ampules overnight in 6N hydrochloride with 6 mL/100 mg dry tissue. Samples were then filtered through Whatman 3 filter paper (Sigma-Aldrich, St. Louis, Missouri) and dried under a vacuum. Dried samples were suspended in 4 mL of distilled water, and the pH was adjusted to 6.0 with 1N sodium hydroxide. Isopropanol (4 mL) was added, and 60 L of this solution was increased to 400 L by adding acetate-citrate-isopropanol (1:1:1). After incubation at 25°C for 5 minutes, 100 L of oxidant buffer and 1300 L of Ehrlich's reagent were added. After incubation at 60°C for 30 minutes, absorption at 558 nm was measured. Tissue hydroxyproline concentrations were calculated from a standard curve using hydroxyproline concentrations in the range of 0.5–5.0 g. Data were expressed as μg/mL of dry tissue weight.[30]

Histochemical Observation

Transverse sections (5 μm) were taken from the paraffin blocks using a rotary microtome (RM 2135, Leica Microsystems, Wetzlar, Germany) and prepared for both histochemical and terminal deoxynucleotidyltransferase-biotin nick end-label (TUNEL) staining. Sections dewaxed at 60°C overnight were immersed in xylene for 1 hour and then rehydrated through a graded ethanol series (100%, 95%, 80%, 70%, and 60%) for 2 minutes at each concentration. They were then washed in tap water. After 2 minutes of staining with hematoxylin and eosin (HE) (01562E, Surgipath Europe Ltd., Bretton, Peterborough, United Kingdom), the sections were rewashed for 5 minutes to prevent overstaining. Thereafter, sections were stained with HE 01602E (Surgipath Europe Ltd.) according to the company's protocol.[31] Slides were mounted using a mounting medium (Entellan®, UN 1866, Merck, Darmstadt, Germany) and covered with glass coverslips prior to being photographed under light microscopy (BX-40, Olympus America Inc., Melville, New York) by one investigator (S.V.), who was blinded to the treatment protocol.

The liver samples were stored to protect them from light. Tissue sections were fixed in 10% neutral buffered formalin and embedded in paraffin. Paraffin sections were stained with HE and were examined and scored by a pathologist who was blinded to the treatment protocol. Histopathologic evaluation was performed twice in 4 sections per slide for each animal.

DETECTION OF APOPTOTIC CELL DEATH IN SITU USING THE TUNEL METHOD

Fragmentation of DNA in the nucleus is one of the first morphologic changes of the apoptotic process. To detect the fragmentation in histologic sections, we used a commercial TUNEL-method kit (DeadEnd Colorimetric TUNEL System Kit, Roche-USA, Nutley, New Jersey) according to the manufacturer's instructions.[32,33] Paraffin was removed from the sections using xylene; the sections were then rehydrated and postfixed with 4% paraformaldehyde for 10 minutes. They were then incubated with proteinase K 20 µg/mL for 10 minutes and rinsed in distilled water for 5 minutes. Endogenous peroxidase activity was inhibited with 3% hydrogen peroxide. The sections were incubated in equilibration buffer for 10 to 15 seconds and then in terminal deoxynucleotidyl transferase (TdT) enzyme in a humidified atmosphere at 37°C for 60 minutes. They were subsequently placed in prewarmed working-strength stop/wash buffer at room temperature for 10 minutes and incubated with antistreptavidin-peroxidase for 45 minutes. Each step was separated by careful washing in phosphate-buffered saline. Staining was done with 3,3'-diaminobenzidine and counterstaining was performed in Mayer's hematoxylin. The slides were examined independently by one of the authors (S.V.), who was blinded to the results of the routine histologic examination. Approximately 100 TUNEL-positive cells per case were counted randomly in chosen fields. The percentage of apoptotic cells stained brown was determined. Cells in areas with necrosis or poor morphology or cells in the margins of sections were not analyzed. As negative staining, control for TdT enzyme was omitted during the tailing reactions.[32,33]

STATISTICAL ANALYSIS

Statistical analysis was performed using SPSS version 10.0 (SPSS Inc., Chicago, Illinois). Data were expressed as mean (SEM). The Mann-Whitney U test was used for nonparametric data, and the t test and 1-way analysis of variance (ANOVA) with the Tukey test were used for parametric data. The mean differences in hepatic hydroxyproline content and MDA concentration among groups were analyzed using 1-way ANOVA and confirmed using the Student-Newman-Keuls test. Histomorphologic data for TUNEL positivity were compared using 1-way ANOVA. $P < 0.05$ was considered statistically significant.

RESULTS

EXPERIMENTAL SUBJECTS

Thirty-two adult male Sprague-Dawley rats were assigned to 1 of 4 groups: silymarin group (n = 7), PTX group (n = 7), sham group (n = 9), and control group (n = 9).

MATRIX METALLOPROTEINASE AND TISSUE INHIBITOR OF MATRIX METALLOPROTEINASE ACTIVITY

The effects of liver injury on ECM proteinase and collagen cascade via tissue MMP-1 and -2 and TIMP-1 and -2 activity and TGF-β_1 and hydroxyproline concentration were evaluated (**Table I**). Mean (SEM) MMP-1 activity was similar in all groups. MMP-2 activity was significantly lower in the silymarin and PTX groups compared with the control group (57.35 [9.89] and 46.88 [9.56] vs 232.32 [79.76] μg/mL, respectively; both, $P = 0.04$). MMP-2 activity was similar in the silymarin and PTX groups. Hepatic TIMP-1 activity was similar in all groups. Compared with the control group (1.37 [0.38] μg/mL), hepatic TIMP-2 activity was significantly lower in the silymarin group (0.55 [0.13] μg/mL; $P = 0.04$) and the PTX group (0.42 [0.09] μg/mL; $P = 0.01$), but no statistically significant difference was found between the silymarin and PTX groups (**Figures 1–3**).

The highest TGF-β_1 concentration was found in the control group (909.17 [117.35]). Compared with the control group, TGF-β_1 concentration was significantly lower in the silymarin and PTX groups (518.24 [30.34] and 519.57 [47.27] μg/mL, respectively; both, $P = 0.01$). There was no significant difference in TGF-β_1 concentration between the silymarin and PTX groups (**Table I**).

Tissue hydroxyproline concentration was highest in the control group (0.70 [0.08] μg/mL). The sham group (0.26 [0.04] μg/mL) had significantly lower hydroxyproline concentration compared with the silymarin group (0.60 [0.14] μg/mL; $P = 0.04$), the PTX group (0.58 [0.10] μg/mL; $P = 0.04$), and the control group (0.70 [0.08] μg/mL; $P = 0.01$). The hydroxyproline concentration was not significantly different between the silymarin or PTX groups compared with the control group.

Table I. Mean (SEM) matrix metalloproteinase (MMP) and tissue inhibitor of MMP (TIMP) activity and transforming growth factor (TGF)-β_1 and hydroxyproline concentration after 10 days of treatment in the silymarin, pentoxifylline (PTX), sham, and control groups (N = 32). All data are μg/mL.

Variable	Silymarin (n = 7)	PTX (n = 7)	Sham (n = 9)	Control (n = 9)
MMP-1	0.17 (0.02)	0.15 (0.01)	0.17 (0.02)	0.22 (0.02)
MMP-2	57.35 (9.89)*	46.88 (9.56)*	80.05 (19.6)	232.32 (79.76)
TIMP-1	0.53 (0.05)	0.45 (0.10)	0.45 (0.05)	0.74 (0.26)
TIMP-2	0.55 (0.13)*	0.42 (0.09)*	0.43 (0.05)	1.37 (0.38)
TGF-β_1	518.24 (30.34)*	519.57 (47.27)*	571.44 (42.17)	909.17 (117.35)
Hydroxyproline	0.60 (0.14)†	0.58 (0.10)†	0.26 (0.04)*	0.70 (0.08)

*$P < 0.05$ versus control.
†$P < 0.05$ versus sham.

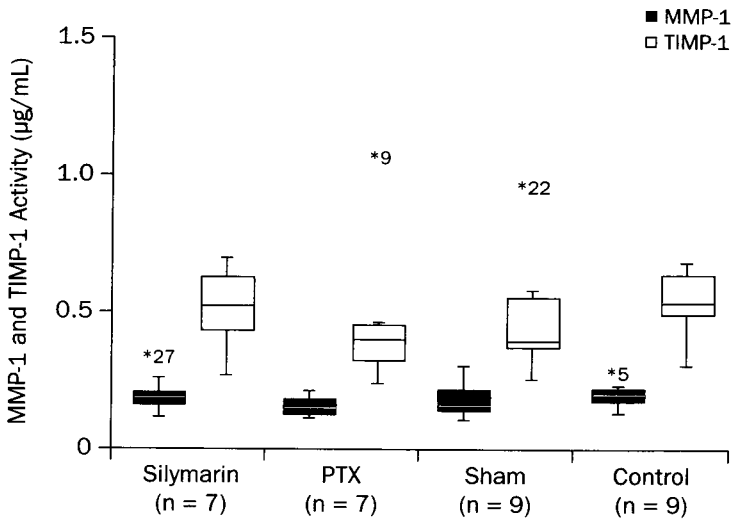

Figure 1. Mean (SD) and range of matrix metalloproteinase (MMP)-1 and tissue inhibitor of MMP (TIMP)-1 activity by group in adult male Sprague-Dawley rats. PTX = pentoxifylline. *Outlier data with subject number.

HISTOMORPHOLOGY/APOPTOSIS

Data for histomorphologic changes in liver seen under light microscopy are shown in Table II. In the sham group, the hepatocytes were normal, active cells had vesicular nuclei, and cytoplasm was basophilic. No polymorph nuclear leukocyte (PNL) infiltration was observed in the sham group. In the control group, hepatocyte cyto-

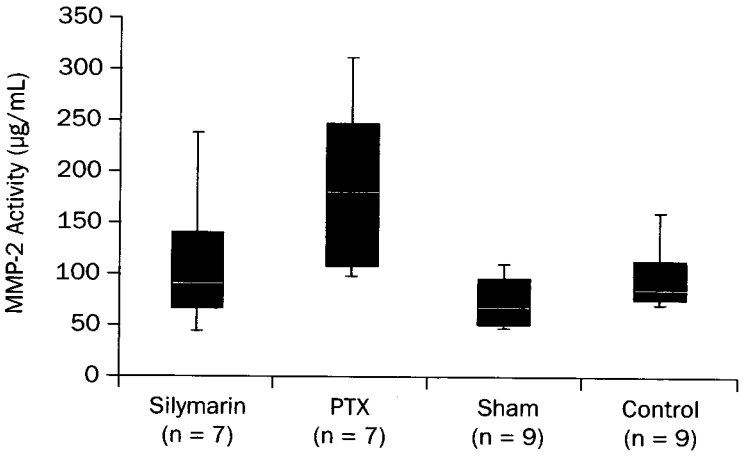

Figure 2. Mean (SD) and range of matrix metalloproteinase (MMP)-2 activity by group in adult male Sprague-Dawley rats. PTX = pentoxifylline.

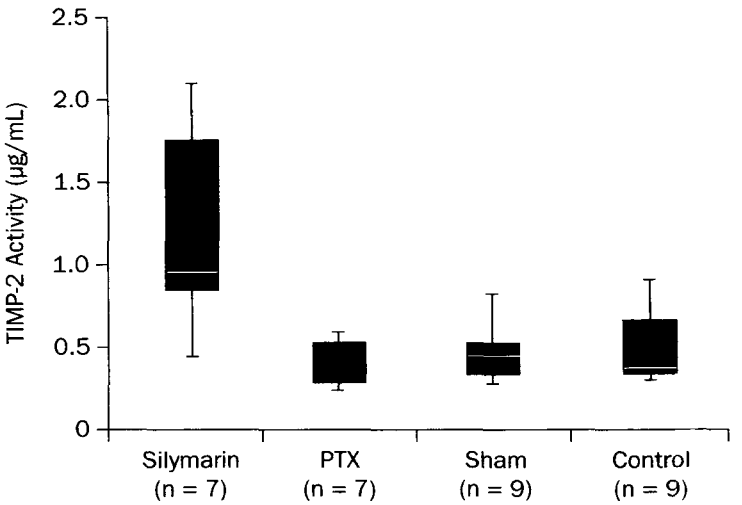

Figure 3. Mean (SD) and range of tissue inhibitor of matrix metalloproteinase (TIMP)-2 activity by group in adult male Sprague-Dawley rats. PTX = pentoxifylline.

plasm was basophilic and nuclei were picnotic. Moreover, severe PNL infiltration was observed in periportal and sinusoidal areas. The ratio of TUNEL-positive cells was 1.2 (0.13), 3.8 (0.34), 0.3 (0.15), and 14.6 (2.44) in the silymarin, PTX, sham, and control groups, respectively. The ratio of TUNEL-positive cells in the control

Table II. Mean (SEM) data for histomorphologic changes seen under light microscopy after 10 days of treatment in the silymarin, pentoxifylline (PTX), sham, and control groups (N = 32).

Variable	Silymarin (n = 7)	PTX (n = 7)	Sham (n = 9)	Control (n = 9)
CHM	1.43 (0.20)	2.00 (0.22)*†	2.22 (0.22)*	1.11 (0.11)
Hemorrhage	1.29 (0.18)†	1.57 (0.20)*†	2.44 (0.29)	1.00 (0)†
Sinusoidal dilatation	1.57 (0.20)*†	1.71 (0.18)*	2.22 (0.22)*	1.00 (0)
PPCI	2.57 (0.20)†	2.14 (0.26)†	3.44 (0.24)	1.00 (0)†
Necrosis	1.00 (0)‡	1.71 (0.29)*	1.44 (0.24)	1.22 (0.15)‡
Inflammation	2.57 (0.20)†	2.14 (0.26)†	3.44 (0.24)	1.00 (0)†

CHM = changes in hepatocyte morphology; PPCI = presinusoidal polymorphonuclear cell infiltration.
*$P < 0.05$ versus control.
†$P < 0.05$ versus sham.
‡$P < 0.05$ versus PTX.

group was significantly higher compared with the sham, silymarin, and PTX groups (all, $P = 0.001$). PTX and silymarin were both associated with significantly reduced apoptosis compared with the control group; silymarin (1.2 [0.13]) reduced apoptosis significantly, more than PTX (3.8 [0.34]; $P = 0.04$).

Changes in hepatocyte morphology (CHM), hemorrhage, sinusoidal dilatation, presinusoidal polymorphonuclear cell infiltration (PPCI), necrosis, and periportal inflammation were evaluated using light microscopy (**Table II**). Compared with the control group (1.11 [0.11]), CHM score was significantly higher in the PTX group (2.00 [0.22]; $P = 0.008$) and the sham group (2.22 [0.22]; $P = 0.002$). CHM score was not significantly different in the silymarin group compared with the PTX group. Compared with the sham group (2.44 [0.29]), hemorrhage was significantly less severe in the silymarin group (1.29 [0.18]; $P = 0.04$), the PTX group (1.57 [0.20]; $P = 0.04$), and the control group (1.00 [0]; $P < 0.001$). There was no significant difference between the silymarin group and the PTX group. The number of animals with sinusoidal dilatation was significantly greater in the silymarin group (1.57 [0.20]; $P = 0.04$), the PTX group (1.71 [0.18]; $P = 0.04$), and the sham group (2.22 [0.22]; $P < 0.001$), compared with control group (1.00 [0]); no statistically significant difference was found between the silymarin and PTX groups. Compared with the sham group (3.44 [0.24]), PPCI was significantly less severe in the silymarin group (2.57 [0.20]; $P = 0.03$), the PTX group (2.14 [0.26]; $P = 0.008$), and the control group (1.00 [0]; $P < 0.001$). No statistically significant difference was found in PPCI in the silymarin group compared with the PTX group. Necrosis was significantly greater in the PTX group (1.71 [0.29]) compared with the silymarin group (1.00 [0]; $P = 0.007$) and the control group (1.22 [0.15]; $P = 0.048$). Compared with the sham group (3.44 [0.24]), inflammation was significantly less severe in the silymarin group (2.57 [0.20]; $P = 0.03$), the PTX group (2.14 [0.26]; $P = 0.008$), and the control group (1.00 [0]; $P < 0.001$).

LIVER FUNCTION AND LIPID PEROXIDATION

Biochemical parameters showing hepatic function and the status of lipid peroxidation analyzed via MDA concentration are shown in **Table III**. Liver function was monitored by measuring plasma total and indirect bilirubin concentration and AST, ALT, and GGT activity. In the control group, all biochemical markers were elevated after CBDL, indicating liver injury. Bilirubin concentrations were significantly lower in the sham group compared with the control group—total bilirubin (0.52 [0.07] vs 9.24 [0.63] U/L; $P < 0.001$) and indirect bilirubin (0.48 [0.06] vs 3.79 [0.18]; $P < 0.001$). Total and indirect bilirubin concentrations in the silymarin group and the PTX group were not statistically significantly different compared with the control group. These values were also similar between the silymarin and PTX groups. AST activity in the sham group was significantly lower compared with the control group (100.77 [8.68] vs 630.00 [46.80] U/L; $P = 0.001$). AST activity was also significantly lower in the silymarin group (443.11 [78.73]; $P = 0.04$) and the PTX group (349.42 [34.00]; $P = 0.03$). AST activity was not significantly different between the silymarin and PTX groups. Compared with the sham group (35.66 [2.34]), ALT activity was significantly higher in the sily-

Table III. Mean (SEM) values of liver function tests after 10 days of treatment in the silymarin, pentoxifylline (PTX), sham, and control groups (N = 32).

Variable	Silymarin (n = 7)	PTX (n = 7)	Sham (n = 9)	Control (n = 9)
Total bilirubin, U/L	8.85 (0.63)*	8.95 (0.54)*	0.52 (0.07)†	9.24 (0.63)
Indirect bilirubin, U/L	3.35 (0.29)*	3.59 (0.18)*	0.48 (0.06)†	3.79 (0.18)
AST, U/L	443.11 (78.73)*†	349.42 (34.00)*†	100.77 (8.68)†	630.00 (46.8)
ALT, U/L	86.14 (4.97)*†	84.14 (11.21)*†	35.66 (2.34)	191.12 (32.93)*
GGT, U/L	22.95 (4.03)*	27.75 (4.17)*	3.53 (0.73)	67.38 (11.35)*
MDA, nmol/mL	0.08 (0.01)†‡	0.11 (0.02)†	0.14 (0.02)†	0.22 (0.03)

AST = aspartate aminotransferase; ALT = alanine aminotransferase; GGT = γ-glutamyltransferase; MDA = malondialdehyde.
*$P < 0.05$ versus sham.
†$P < 0.05$ versus control.
‡$P < 0.05$ versus PTX.

marin group (86.14 [4.97] U/L; $P < 0.001$), the PTX group (84.14 [11.21]; $P < 0.001$), and the control group (191.12 [32.93]; $P < 0.001$). ALT activity was significantly lower in the silymarin and PTX groups compared with the control group (both, $P = 0.04$). Compared with the sham group (3.53 [0.73]), GGT activity was significantly higher in the silymarin group (22.95 [4.03]; $P < 0.001$), the PTX group (27.75 [4.17]; $P < 0.001$), and the control group (67.38 [11.35]; $P = 0.007$).

Based on MDA concentrations, CBDL was associated with lipid peroxidation. Compared with the control group (0.22 [0.03] nmol/mL), MDA concentration was significantly lower in the silymarin group (0.08 [0.01]; $P = 0.004$), the PTX group (0.11 [0.02]; $P = 0.04$), and the sham group (0.14 [0.02]; $P = 0.04$). MDA concentration was significantly lower in the silymarin group compared with the PTX group ($P = 0.03$) (Table III).

DISCUSSION

Substantial progress has been made in understanding the cellular and molecular regulation of hepatic fibrosis.[3–6] Excessive accumulation of ECM in fibrotic liver diseases is a dynamic process that is mainly regulated by HSCs, which might therefore represent the main target for antifibrotic therapies.[3–6] Hepatic fibrogenesis is associated with hepatocellular necrosis and inflammation, and HSCs are regarded as the primary target cells for inflammatory stimuli in the injured liver.[3,4]

Silymarin and silybin have been reported to activate hepatocyte ribonuclease polymerase II, to restore the adenosinetriphosphatase activity and glutathione content, and to prevent oxidative membrane damage.[34,35] Silymarin has been reported to prevent or attenuate acute liver injury caused by carbon tetrachloride,[21] paracetamol,[22]

D-galactosamine,[23] ischemia/reperfusion,[36] and radiation.[37] Two studies suggested that silymarin prevents fibrosis induced by carbon tetrachloride.[38] However, in the rat model and related animal models, the antifibrotic effect of silymarin may result from its antioxidant and radical scavenging properties. In our study, the silymarin group had a lower MDA concentration and was associated with greater suppression of lipid peroxidation than the PTX group. Moreover, using the model of secondary biliary fibrosis after complete CBDL, which results in progressive fibrosis in the absence of inflammation and necrosis, silymarin was found to prevent hepatic collagen accumulation,[39,40] as was found in this study. Fibrosis was found to result from increased synthesis and deposition (ie, fibrogenesis) and/or decreased degradation and removal (ie, fibrolysis) of ECM components.[41] TGF-β_1, a multifunctional growth factor, plays an important role as a profibrogenic factor in chronic liver disease, triggering the expression of procollagen I and TIMP-1, key effectors of fibrogenesis.[42] TGF-β is the most potent fibrogenic cytokine described for HSCs and stimulates the synthesis and deposition of ECM components (eg, elastin, tenascin, osteonectin, biglycan, decorin, and types I, III, and IV collagen).[42,43] HSCs are a major source of TGF-β_1, but Kupffer cells, hepatocytes, and platelets can also secrete this cytokine.[41–46] In biliary fibrosis, hepatic expression of TGF-β, procollagen α1, and TIMP-1 is highly upregulated.[44–46] Our study found that hepatic TGF-β_1 concentrations markedly increased in experimental liver fibrosis. Treatment with both silymarin and PTX significantly decreased TGF-β_1 concentration versus control.

Hepatotoxicity may be the result of primary apoptosis.[47] Hepatotoxins (eg, nitrosamines) have been found to induce DNA fragmentation in vivo, and the formation of apoptotic bodies has been observed after treatment of animals with ethanol, dimethylnitrosamine, and carbon tetrachloride.[48] Proapoptotic cytokines (eg, TNF, TGF-β, and PDGF) are major cytokines involved in fibrogenesis. Several studies have examined the role of fibroblast apoptosis and the influence of cytokines generated by the fibrogenesis cascade on hepatocyte apoptosis. An autocrine cytokine loop exists for the fibrogenic cytokine TGF-β. Gressner et al[49] found that hepatic myofibroblasts, which are transformed HSCs, participated in hepatocyte apoptosis by paracrine loops involving TGF-β. This is additional evidence for the perpetuation of fibrogenesis. Iredale et al[50] found that HSC activation was associated with expression of the cell cycle and apoptosis of the HSC regulatory Myc proto-oncogene protein. Conversely, in livers allowed to spontaneously recover from fibrosis, the number of apoptotic bodies increased. These data suggest that HSC activation may be associated with inhibition of apoptosis which is responsible for activation and proliferation of HSCs. Therefore, the inhibition of HSC apoptosis could be a target for antifibrotic strategies. Ursodeoxycholic acid is one of the drugs that has been found to be effective in treating primary biliary cirrhosis.[11] Silymarin and phosphatidylcholine are currently being evaluated in clinical trials. However, these are not true antifibrotic agents. In our study, silymarin and PTX both showed cytoprotective effects. As cytoprotective agents, they work at least in part by inhibiting hepatocyte apoptosis.

This study had some limitations. Hepatic fibrosis is a complex process in which interaction between apoptosis in HSCs and regulation of MMPs should be studied not

only in animals but also in humans. In this study, we measured the effects of 10 days of drug treatment after CBDL. However, histomorphologic and biochemical changes and the balance between other MMPs and TIMPs could also be analyzed on days 3, 7, and 21 of treatment. This might provide varying results and deserves further investigation. Different doses of silymarin and PTX in this experimental liver fibrosis model might also be investigated.

CONCLUSIONS

Silymarin and PTX were associated with lower histopathologic liver damage, hepatocyte apoptosis, and regulation of ECM proteins. Lipid peroxidation in hepatocytes was lower in the silymarin group compared with the PTX group. Silymarin and PTX appeared to have hepatoprotective effects in this experimental liver fibrosis model, but further clinical and experimental studies are needed.

ACKNOWLEDGMENT

The present study was supported by the Medical Research Foundation of Celal Bayar University, Manisa, Turkey.

REFERENCES

1. Gonzalo T, Talman EG, van de Ven A, et al. Selective targeting of pentoxifylline to hepatic stellate cells using a novel platinum-based linker technology. *J Control Release.* 2006;111:193–203.
2. Aksun SA, Özmen D, Bayındır O. Metalloproteinazlar, inhibitörleri ve iliskili fizyolojik ve patolojik durumlar. *Turk Klin J Med Sci.* 2001;21:332–342.
3. Friedman SL. Molecular regulation of hepatic fibrosis, an integrated cellular response to tissue injury. *J Biol Chem.* 2000;275:2247–2250.
4. Friedman SL. Cytokines and fibrogenesis. *Semin Liver Dis.* 1999;19:129–140.
5. Di Sario A, Bendia E, Taffetani S, et al. Selective Na+/H+ exchange inhibition by cariporide reduces liver fibrosis in the rat. *Hepatology.* 2003;37:256–266.
6. Bataller R, Brenner DA. Liver fibrosis [published correction appears in *J Clin Invest.* 2005;115:1100]. *J Clin Invest.* 2005;115:209–218.
7. Raetsch C, Jia JD, Boigk G, et al. Pentoxifylline downregulates profibrogenic cytokines and procollagen I expression in rat secondary biliary fibrosis. *Gut.* 2002;50:241–247.
8. Chen YM, Wu KD, Tsai TJ, Hsieh BS. Pentoxifylline inhibits PDGF-induced proliferation of and TGF-beta-stimulated collagen synthesis by vascular smooth muscle cells. *J Mol Cell Cardiol.* 1999;31:773–783.
9. Gude RP, Binda MM, Boquete AL, Bonfil RD. Inhibition of endothelial cell proliferation and tumor-induced angiogenesis by pentoxifylline. *J Cancer Res Clin Oncol.* 2001;127:625–630.
10. Berman B, Duncan MR. Pentoxifylline inhibits normal human dermal fibroblast in vitro proliferation, collagen, glycosaminoglycan and fibronectin production, and increases collagenase activity. *J Invest Dermatol.* 1989;92:605–610.
11. Duncan MR, Hasan A, Berman B. Pentoxifylline, pentifylline and interferons decrease type I and III procollagen mRNA levels in dermal fibroblasts: Evidence for mediation by nuclear factor 1 down-regulation. *J Invest Dermatol.* 1995;104:282–286.
12. Friedman SL. Closing in on the signals of hepatic fibrosis. *Gastroenterology.* 1997;112:1406–1409.
13. Bergman I, Loxley R. The determination of hydroxyproline in urine hydrolysates. *Clin Chim Acta.* 1970;27:347–349.

14. Wu J, Zern MA. Hepatic stellate cells: A target for the treatment of liver fibrosis. *J Gastroenterol.* 2000;35:665–672.
15. Wu J, Kuncio GS, Zern MA. Human liver growth in fibrosis and cirrhosis. In: Swain A, Diehl A-M, eds. *Liver Growth and Repair.* New York, NY: Chapman and Hall; 1997:558–576.
16. Roeb E, Purucker E, Breuer B, et al. TIMP expression in toxic and cholestatic liver injury in rat. *J Hepatol.* 1997;27:535–544.
17. Leroy V, Monier F, Bottari S, et al. Circulating matrix metalloproteinases 1, 2, 9 and their inhibitors TIMP-1 and TIMP-2 as serum markers of liver fibrosis in patients with chronic hepatitis C: Comparison with PIIINP and hyaluronic acid. *Am J Gastroenterol.* 2004;99:271–279.
18. Iredale JP. Tissue inhibitors of metalloproteinases in liver fibrosis. *Int J Biochem Cell Biol.* 1997;29:43–54.
19. Arthur MJ. Fibrogenesis II. Metalloproteinases and their inhibitors in liver fibrosis. *Am J Physiol Gastrointest Liver Physiol.* 2000;279:G245–G249.
20. Arthur MJ. Degradation of matrix proteins in liver fibrosis. *Path Res Pract.* 1994;190:825–833.
21. Benyon RC, Iredale JP. Is liver fibrosis reversible? *Gut.* 2000;46:443–446.
22. Okazaki I, Watanabe T, Hozawa S, et al. Molecular mechanism of the reversibility of hepatic fibrosis: With special reference to the role of matrix metalloproteinases. *J Gastroenterol Hepatol.* 2000;15(Suppl):D26–D32.
23. Schuppan D, Jia JD, Brinkhaus B, Hahn EG. Herbal products for liver diseases: A therapeutic challenge for the new millennium. *Hepatology.* 1999;30:1099–1104.
24. Sonnenbichler J, Zetl I. Biochemical effects of the flavonolignane silibinin on RNA, protein and DNA synthesis in rat livers. *Prog Clin Biol Res.* 1986;213:319–331.
25. Lettéron P, Labbe G, Degott C, et al. Mechanism for the protective effects of silymarin against carbon tetrachloride-induced lipid peroxidation and hepatotoxicity in mice. Evidence that silymarin acts both as an inhibitor of metabolic activation and as a chain-breaking antioxidant. *Biochem Pharmacol.* 1990;39:2027–2034.
26. Kropácová K, Misúrová E, Hacová H. Protective and therapeutic effect of silymarin on the development of latent liver damage. *Radiats Biol Radioecol.* 1998;38:411–415.
27. Fuchs EC, Weyhenmeyer R, Weiner OH. Effects of silibinin and of a synthetic analogue on isolated rat hepatic stellate cells and myofibroblasts. *Arzneimittelforschung.* 1997;47:1383–1387.
28. Kim MY, Baik SK, Jang YO, et al. Serum hyaluronic acid level: Correlation with quantitative measurement of hepatic fibrosis in a cirrhotic rat model [in Korean]. *Korean J Hepatol.* 2008;14: 159–167.
29. Chiariello M, Ambrosio G, Cappelli-Bigazzi M, et al. A biochemical method for the quantitation of myocardial scarring after experimental coronary artery occlusion. *J Mol Cell Cardiol.* 1986;18:283–290.
30. Haková H, Misúrová E, Kropácová K. The effect of silymarin on concentration and total content of nucleic acids in tissues of continuously irradiated rats. *Vet Med (Praha).* 1996;41: 113–119.
31. Miller K. Immunocytochemical techniques. In: Bancroft JD, Gamble M, eds. *Theory and Practice of Histological Techniques.* 5th ed. Edinburgh, UK: Churchill Livingstone; 2002:421–464.
32. Gold R, Schmied M, Giegerich G, et al. Differentiation between cellular apoptosis and necrosis by the combined use of in situ tailing and nick translation techniques. *Lab Invest.* 1994; 71:219–225.

33. Negoescu A, Guillermet C, Lorimier P, et al. Importance of DNA fragmentation in apoptosis with regard to TUNEL specificity. *Biomed Pharmacother.* 1998;52:252–258.
34. Ohkawa H, Ohishi N, Yagi K. Assay for lipid peroxides in animal tissues by thiobarbituric acid reaction. *Anal Biochem.* 1979;95:351–358.
35. Bendia E, Benedetti A, Baroni GS, et al. Effect of cyanidin 3-O-beta-glucopyranoside on hepatic stellate cell proliferation and collagen synthesis induced by oxidative stress. *Dig Liver Dis.* 2005;37:342–348.
36. Calès P. Apoptosis and liver fibrosis: Antifibrotic strategies. *Biomed Pharmacother.* 1998;52: 259–263.
37. Saito JM, Maher JJ. Bile duct ligation in rats induces biliary expression of cytokine-induced neutrophil chemoattractant. *Gastroenterology.* 2000;118:1157–1168.
38. Valenzuela A, Garrido A. Biochemical bases of the pharmacological action of the flavonoid silymarin and of its structural isomer silibinin. *Biol Res.* 1994;27:105–112.
39. Ferenci P, Dragosics B, Dittrich H, et al. Randomized controlled trial of silymarin treatment in patients with cirrhosis of the liver. *J Hepatol.* 1989;9:105–113.
40. Parés A, Planas R, Torres M, et al. Effects of silymarin in alcoholic patients with cirrhosis of the liver: Results of a controlled, double-blind, randomized and multicenter trial. *J Hepatol.* 1998;28:615–621.
41. Muriel P, Mourelle M. Prevention by silymarin of membrane alterations in acute CCl4 liver damage. *J Appl Toxicol.* 1990;10:275–279.
42. Muriel P, Garciapiña T, Perez-Alvarez V, Mourelle M. Silymarin protects against paracetamol-induced lipid peroxidation and liver damage. *J Appl Toxicol.* 1992;12:439–442.
43. Gerling B, Becker M, Waldschmidt J, et al. Elevated serum aminoterminal procollagen type-III-peptide parallels collagen accumulation in rats with secondary biliary fibrosis. *J Hepatol.* 1996;25:79–84.
44. Olaso E, Friedman SL. Molecular regulation of hepatic fibrogenesis. *J Hepatol.* 1998;29:836–847.
45. Zheng WD, Zhang LJ, Shi MN, et al. Expression of matrix metalloproteinase-2 and tissue inhibitor of metalloproteinase-1 in hepatic stellate cells during rat hepatic fibrosis and its intervention by IL-10. *World J Gastroenterol.* 2005;11:1753–1758.
46. Overall CM, Wrana JL, Sodek J. Independent regulation of collagenase, 72-kDa progelatinase, and metalloendoproteinase inhibitor expression in human fibroblasts by transforming growth factor-beta. *J Biol Chem.* 1989;264:1860–1869.
47. Leist M, Gantner F, Naumann H, et al. Tumor necrosis factor-induced apoptosis during the poisoning of mice with hepatotoxins. *Gastroenterology.* 1997;112:923–934.
48. Galle PR. Apoptosis in liver disease. *J Hepatol.* 1997;27:405–412.
49. Gressner AM, Polzar B, Lahme B, Mannherz HG. Induction of rat liver parenchymal cell apoptosis by hepatic myofibroblasts via transforming growth factor beta. *Hepatology.* 1996;23: 571–581.
50. Iredale JP, Northrop M, Vincent K, et al. Possible role of apoptosis in regulating activated stellate cell numbers during liver injury. *J Hepatol.* 1997;26(Suppl 1):132. Abstract P/C09/09.

ADDRESS CORRESPONDENCE TO: Eray Kara, MD, Mithatpasa cd. No:394/5. Catalkaya apt., PC.35260, Karatas-Izmir, Turkey. E-mail: eraykara@hotmail.com