Ann Thorac Cardiovasc Surg 2018; 24: 127–130
Online March 16, 2018
doi: 10.5761/atcs.oa.17-00220

Original Article

Oblique Chest X-Ray: An Alternative Way to Detect Pneumothorax

Cumhur Murat Tulay, MD,[1*] Sadık Yaldız, MD,[1*] and Adnan Bilge, MD[2*]

Purpose: To identify occult pneumothorax with oblique chest X-ray (OCXR) in clinically suspected patients.
Methods: In this retrospective study, we examined 1082 adult multitrauma patients who were admitted to our emergency service between January 2016 and January 2017. Clinical findings that suggest occult pneumothorax were rib fracture, flail chest, chest pain, subcutaneous emphysema, abrasion or ecchymosis and moderate to severe hypoxia in clinical parameters. All of these patients underwent anteroposterior chest X-ray (APCXR), but no pneumothorax could be detected. Upon this, OCXR was performed using mobile X-ray equipment.
Results: Traumatic pneumothorax was observed in 421 (38.9%) of 1082 patients. We applied OCXR to 26 multitrauma patients. Occult pneumothorax was evaluated at 22 patients (2.03%) in 1082 multitrauma patients. The 22 patients who had multitrauma occult pneumothorax on OCXR were internated at intensive care unit (ICU) and follow-up was done using OCXR and APCXR.
Conclusions: OCXR can be an alternative imaging technique to identify occult pneumothorax in some trauma patients at emergency room and also follow period at ICU.

Keywords: occult pneumothorax, pneumothorax, chest X-ray, oblique graphy

Introduction

A lot of previously undetermined thoracic pathologies which are not diagnosed on chest X-ray have been identified by use of computed tomography (CT) in the diagnosis of trauma.[1,2] The standard anteroposterior supine X-ray (APSXR) is the recommended imaging modality for trauma patients according to the Advanced Trauma Life Support Course guideline.[3,4]

A pneumothorax identified on CT which is not seen on supine chest X-ray is recognized as "occult pneumothorax."[1,3,5,6] Although chest X-ray is the principal radiological imaging technique for thorax, occult pneumothorax cannot be detected for 52%–63% of all traumas.[1,7]

Early recognition of occult pneumothorax is very important because it can progress to tension pneumothorax and it is life-threatening condition.[1,8] Tension pneumothorax can be resulted from receiving mechanical ventilation after occult pneumothorax.[3,9] CT cannot be performed in patients who have severe shock, need of immobilization and/or performing mechanical ventilation in intensive care units (ICUs). The goal of this study was to show the effectiveness of oblique chest X-ray

[1]*Thoracic Surgery Department, Manisa Celal Bayar University, School of Medicine, Manisa, Turkey*
[2]*Emergency Department, Manisa Celal Bayar University, School of Medicine, Manisa, Turkey*

Received: November 24, 2017; Accepted: January 19, 2018
Corresponding author: Cumhur Murat Tulay, MD. Thoracic Surgery Department, Manisa Celal Bayar University, School of Medicine, Manisa Celal Bayar University, Sehit Prof. Dr. Ilhan Varank Campus, 45140 Yunusemre, Manisa, Turkey
Email: cumhurtulay@hotmail.com
©2018 The Editorial Committee of *Annals of Thoracic and Cardiovascular Surgery*. This work is licensed under a Creative Commons Attribution-NonCommercial-NonDerivatives International License.
[*]All authors contributed equally to literature search, data collection, study design, analysis of data, manuscript preparation, and review processes. Our study was accepted as oral presentation at "4th International Critical Care and Emergency Medicine Congress and 13th Turkish Emergency Medicine Congress" held in Antalya on May 18–21, 2017.

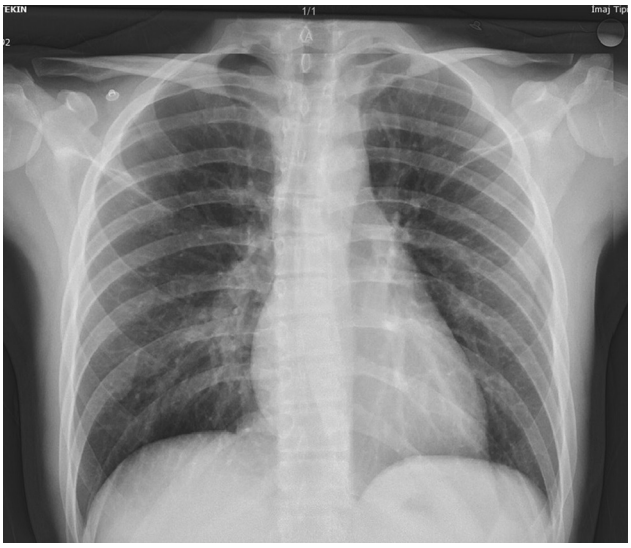

Fig. 1 There is no detectable pneumothorax on APCXR. APCXR: anteroposterior chest X-ray

(OCXR) both in emergency room and follow-up period in ICUs.

Materials and Methods

This retrospective study was performed between January 2016 and January 2017 at emergency room and ICU of a university hospital. We included 1082 adult multitrauma patients. The aim of this study was based on identifying traumatic occult pneumothorax with OCXR in clinically suspected patients over 18 years who should not have performed CT scan for miscellaneous reasons. The ethical approval for conducting this study was obtained from institutional ethics committee. Informed consent was taken from all patients and/or relatives. The criteria for taken OCXR in addition to APCXR that suggest occult pneumothorax were rib fractures, flail chest, chest pain, subcutaneous emphysema, abrasion or ecchymosis at thoracic wall, and moderate to severe hypoxia in clinical parameters. All of these patients underwent APCXR but no pneumothorax could be detected (**Fig. 1**). Then, OCXR was taken and the radiographs were evaluated by a chest surgeon. Diagnosis of occult pneumothorax was done with a distinct visceral pleural line away from the chest wall (**Fig. 2**). Upon this, OCXR was performed using mobile X-ray equipment (Toshiba Rotanode E7240X, Japan). A portable film cassette was set at 30°–60° against a horizontal line in suspected hemithorax. The X-ray beams were directed vertically against the cassette over the pleural interface (**Fig. 3**).

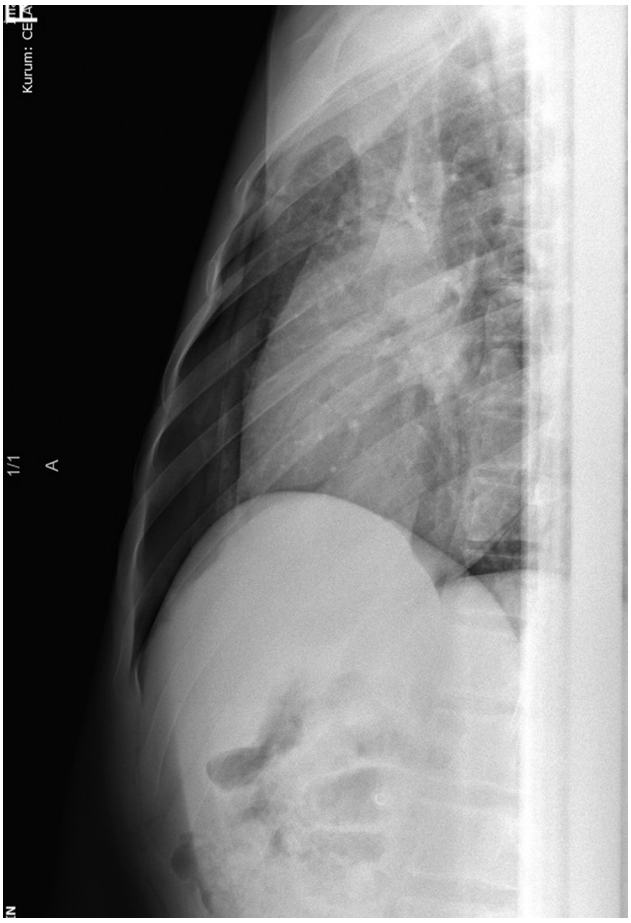

Fig. 2 Occult pneumothorax detected by OCXR. OCXR: oblique chest X-ray



Fig. 3 OCXR technique. OCXR: oblique chest X-ray

Results

We examined 1082 adult multitrauma patients who were admitted to our emergency service between January 2016 and January 2017. Traumatic pneumothorax was observed in 421 (38.9%) of 1082 patients. We applied OCXR to 26 multitrauma patients because of corrupted

CT and/or severe state of shocks, need of immobilization. Occult pneumothorax was evaluated at 22 patients (2.03%) in 1082 multitrauma patients. Multitrauma and accompanying occult pneumothorax patients who were diagnosed at OCXR were internated at ICU and follow-up was done daily using OCXR and APCXR. Chest tube application was not done because of blood gases analysis and about 100% oxygen saturation. We had to performed chest tube to 6 of 22 patients at 3rd or 4th day of follow-up period because of falling of oxygen saturation, receiving mechanical ventilation, and increased pneumothorax level on OCXR.

Discussion

Pneumothorax is one of the most common intrathoracic pathology after trauma. Occult pneumothorax accounts for 52%–63% of all traumas.[1,7] It is sometimes difficult to detect small percentage of pneumothorax with supine APCXR.[7,10] Although CT and ultrasonography are very useful diagnostic tools for pneumothorax, it is difficult to transport patients to CT in severe shock, or perform ultrasonography to patients with multiple rib fractures and sometimes technical failure may be a problem. We think that OCXR may be used in these situations to detect pneumothorax.

Thoracic ultrasonography is an effective and sensitive diagnosing technique to evaluate patients at emergency room.[3,11–16] The diagnostic sensitivity and specificity of thoracic ultrasonography technique for detecting pneumothoraces range from 58.9% to 100% and 94% to 100%, respectively.[7]

Matsumoto reported the sensitivity, specificity, and accuracy of OCXR 61.4%, 99.2%, and 90.9%, respectively, which were very close to thoracic ultrasonography.[3]

Although thoracic ultrasonography has high accuracy rate for pneumothorax, the assessment depends on the technical skill of the person performing ultrasonography. And in such developing country and even in the periphery of developed country, finding trained personnel in this area may not be easy. Operators need to learn thoracic ultrasonography technique.[3]

Although the efficacy of ultrasonography is high in detecting pneumothorax, there may be some problems that will create diagnostic difficulties. Pneumothorax together with tuberculosis, lung contusion, chronic obstructive lung disease, giant bulla, fibroid lung, atelectasis can be difficult to diagnose because of absent sliding signs.[3,14,17–19] Deep sulcus sign could be the only sign for detection of pneumothorax by posteroanterior chest X-ray. There were no suspicious sign related to deep sulcus sign on the initial radiograph of patients in our study.

Subcutaneous emphysema is an important sign for pneumothorax. It may produce comet tail artifacts which can cause false-negative results in thoracic ultrasonography.[3] Ultrasonography is an important diagnostic tool for trauma patients. In this study, we do not propose that OCXR has to be used instead of tomography or thoracic ultrasonography. We recommend OCXR, when ultrasonography cannot be performed for technical reasons or when there is no trained person to identify the occult pneumothorax or with thorax ultrasonography. But a simple oblique chest radiography is an easy way and can be performed and evaluated in anywhere and in every condition. It can be used in ICUs for hemodynamically unstable patients.

Mechanical ventilation is a known risk factor for increasing level of pneumothorax and tension pneumothorax. Decrease in oxygen saturation with mechanical ventilation without any reason needs radiological imaging to exclude pneumothorax. Although physicians can detect high level of pneumothorax with APCXR, horizontal position may prevent pleural markings. For this reason, OCXR could be an alternative to diagnose increased pneumothorax level for follow-up period. We used OCXR both at emergency room and ICU for follow-up period. The most important limitation point of our study was that there was no definitive criterion or guideline for chest tube application for occult pneumothorax. We applied chest tube at ICU according to decreased oxygen saturation together with increased pneumothorax ratio at OCXR. We only said that patient had got pneumothorax more than the first OCXR which was taken at emergency room. Physical examination and oxygen saturation were very important signs for follow-up. The other limitation point is that we have not compared different imaging modalities to observe pneumothorax. We solely wanted to show that OCXR could be an alternative imaging modality for pneumothorax when necessary conditions.

Conclusion

OCXR can be an alternative imaging technique to identify occult pneumothorax in some trauma patients at emergency room and also follow period at ICU. And also this technique may decrease radiation exposure especially for young patients.

Disclosure Statement

The authors declare that they have no conflicts of interest.

References

1) Paschos KA, Boulas K, Vrakas X. Occult post-traumatic pneumothorax: too early to recognise, simply missed or truly occult? Hellenic Journal of Surgery 2012; **84**: 134-41.
2) Kaiser M, Whealon M, Barrios C, et al. The clinical significance of occult thoracic injury in blunt trauma patients. Am Surg 2010; **76**: 1063-6.
3) Matsumoto S, Sekine K, Funabiki T, et al. Diagnostic accuracy of oblique chest radiograph for occult pneumothorax: comparison with ultrasonography. World J Emerg Surg 2016; **11**. doi: 10.1186/s13017-016-0061-x.
4) American College of Surgeons. Commitee on Trauma. Advanced Trauma Life Support Course for doctors. 8th ed. Chicago, IL: American Collage of Surgeon, 2008.
5) Wall SD, Federle MP, Jeffrey RB, et al. CT diagnosis of unsuspected pneumothorax after blunt abdominal trauma. AJR Am J Roentgenol 1983; **141**: 919-21.
6) Moore FO, Goslar PW, Coimbra R, et al. Blunt traumatic occult pneumothorax: is observation safe? results of a prospective, AAST multicenter study. J Trauma 2011; **70**: 1019-23; discussion 1023-5.
7) Matsumoto S, Kishikawa M, Hayakawa K, et al. A method to detect occult pneumothorax with chest radiography. Ann Emerg Med 2011; **57**: 378-81.
8) Chen YC, Lin SF, Liu CJ, et al. Risk factors for ICU mortality in critically ill patients. J Formos Med Assoc 2001; **100**: 656-61.
9) Bridges KG, Welch G, Silver M, et al. CT detection of occult pneumothorax in multiple trauma patients. J Emerg Med 1993; **11**: 179-86.
10) Rhea JT, Novelline RA, Lawrason J, et al. The frequency and significance of thoracic injuries detected on abdominal CT scans of multiple trauma patients. J Trauma 1989; **29**: 502-5.
11) Kirkpatrick AW, Sirois M, Laupland KB, et al. Hand-held thoracic sonography for detecting post-traumatic pneumothoraces: the Extended Focused Assessment with Sonography for Trauma (EFAST). J Trauma 2004; **57**: 288-95.
12) Dulchavsky SA, Schwarz KL, Kirkpatrick AW, et al. Prospective evaluation of thoracic ultrasound in the detection of pneumothorax. J Trauma 2001; **50**: 201-5.
13) Kirkpatrick AW, Ng AK, Dulchavsky SA, et al. Sonographic diagnosis of a pneumothorax inapparent on plain radiography: confirmation by computed tomography. J Trauma 2001; **50**: 750-2.
14) Brook OR, Beck-Razi N, Abadi S, et al. Sonographic detection of pneumothorax by radiology residents as part of extended focused assessment with sonography for trauma. J Ultrasound Med 2009; **28**: 749-55.
15) Nagarsheth K, Kurek S. Ultrasound detection of pneumothorax compared with chest X-ray and computed tomography scan. Am Surg 2011; **77**: 480-4.
16) Soldati G, Testa A, Sher S, et al. Occult traumatic pneumothorax: diagnostic accuracy of lung ultrasonography in the emergency department. Chest 2008; **133**: 204-11.
17) Lichtenstein D, Mezière G, Biderman P, et al. The comet-tail artifact: an ultrasound sign ruling out pneumothorax. Intensive Care Med 1999; **25**: 383-8.
18) Rowan KR, Kirkpatrick AW, Liu D, et al. Traumatic pneumothorax detection with thoracic US: correlation with chest radiography and CT–initial experience. Radiology 2002; **225**: 210-4.
19) Lichtenstein DA, Lascols N, Prin S, et al. The "lung pulse": an early ultrasound sign of complete atelectasis. Intensive Care Med 2003; **29**: 2187-92.